



- Call for help early, from the most experienced staff available
- Stop pulling on the fetal head and ask woman to stop pushing. Note time of birth of head.
- Ask woman to adopt the McRobert's position and apply gentle downwards pressure to the head.
- If no movement after 30s, move to the other manoeuvres. Order is not important.
- Consider the [PAST](#) (posterior axillary sling) technique for difficult cases.
- Prepare for neonatal resus
- Document and debrief the woman.

1. Purpose

Shoulder dystocia is a relatively common event that is difficult to predict; almost half of all cases of shoulder dystocia have no antecedent factors. Anticipation and preparation are the keys to successful management.

Specific manoeuvres must be employed to complete the birth after normal downward traction has failed to deliver the shoulders in a vaginal birth. These manoeuvres are designed to disimpact the fetal shoulder before further traction is applied. Inappropriate and excessive traction is associated with an increased incidence of fetal morbidity, including brachial plexus injuries.

This clinical guideline outlines the requirement for the management of Shoulder Dystocia at the Women's.

2. Definitions

Shoulder dystocia: disproportion between the bisacromial diameter of the fetus and the antero-posterior diameter of the pelvic inlet, the anterior shoulder of the fetus becoming impacted behind the symphysis pubis. Less commonly the posterior shoulder can impact on the maternal sacral promontory.

Pink Alert: a call for immediate obstetric assistance.

3. Responsibilities

- The midwife or medical practitioner who is responsible for the birth to recognize and initiate clinical management of this obstetric emergency
- Midwifery and medical staff providing assistance and or supervision
- Midwife requested to document manoeuvres and timing of same
- Paediatrician who is called upon to resuscitate the infant if required

4. Guideline

4. Principles of care

To assist the safe birth of the baby with minimal morbidity to mother or infant.

4.1. Intrapartum risks

- Prolonged first stage
- Prolonged second stage
- Augmentation of labour
- Instrumental birth



4.2 Recognition

Shoulder dystocia should be immediately suspected when:

- There is difficulty with the birth of the face and chin
- The head is born but remains tightly applied to the vulva
- The chin retracts into the perineum (the turtle sign)
- The anterior shoulder does not birth with normal downward traction

4.2. Management

On recognition of shoulder dystocia, call for help (emergency buzzer) and initiate a pink alert

- Senior midwife
- Additional midwifery staff
- Most experienced obstetric help available
- Paediatrician
- Consider obstetric consultant and anaesthetist
 - Clearly state the problem as 'shoulder dystocia' as help arrives
 - Note the time of the birth of the head
 - Ask the woman to stop pushing
 - Prepare the woman for emergency manoeuvres by laying her flat and removing any pillows from under her back and shoulders.
 - Assist the woman to the end of the bed or remove the end of the bed to make vaginal access easier.

Emergency manoeuvres for the management of shoulder dystocia are designed to do one of three things:

1. Increase the functional size of the bony pelvis
2. Decrease the bisacromial diameter of the fetus
3. Change the relationship of the bisacromial diameter within the bony pelvis by rotating the fetus into the wider oblique diameter

Each of the following manoeuvres should be attempted for up to 30 seconds before moving to the next manoeuvre.

NOTE: Throughout these manoeuvres the shoulders must be rotated using pressure on the scapula or clavicle. Never rotate the head.

AVOID EXCESSIVE TRACTION AT ALL TIMES

Strong downward traction or jerking without disimpacting the shoulder is associated with neonatal trauma including permanent brachial plexus injury. Once the dystocia has been diagnosed and birth attempted, move directly to the manoeuvres. Do not pull further on the fetal head.

AVOID FUNDAL PRESSURE

This is associated with a high rate of brachial plexus injury, uterine rupture and haemorrhage from potential detachment of fundal placenta.



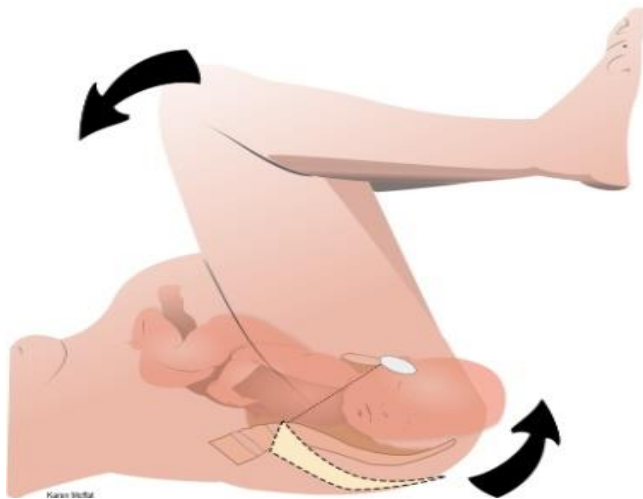
4.3. *McRoberts manoeuvre*

The aim of this procedure is to increase the relative anteroposterior diameter of the pelvic inlet by reducing lumbosacral lordosis. This position has a reported success rate between 40% and 90% ⁸.

Place the woman in a recumbent position.

- Remove or lower the bottom of the bed and manipulate her buttocks to the extreme edge.
- With the aid of an assistant either side, the thighs are abducted and hyperflexed onto the abdomen (McRobert's position).

McRoberts position



4.4. *Suprapubic pressure (also known as Rubin 1)*

The aim of this manoeuvre is to reduce the diameter of the fetal shoulders and rotate the anterior shoulder into the oblique diameter. If this is achieved the shoulder should slip under the symphysis pubis.

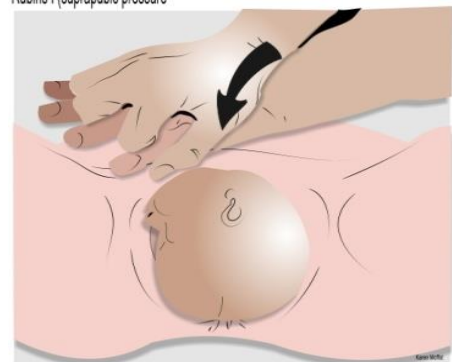
- The accoucheur applies gentle downwards traction to the baby's head.
- Simultaneously the assistant adopts a CPR-hand position over the anterior shoulder. The initial pressure applied is continuous.
- If delivery is unsuccessful, a rocking motion may be applied.

If considering internal manoeuvres this is the time to cut (or extend) an episiotomy (if entering the pelvis is anticipated), as the perineum is clearly visible.

The assistant may be required to elevate the baby's head to improve the view of the perineum (thereby reducing potential trauma to the baby's face).

- This allows the accoucheur to use both hands to cut (or extend) the episiotomy.
- The accoucheur applies gentle downwards traction to the baby's head.

Rubins I (suprapubic pressure)





4.3 Internal manoeuvres

Internal manoeuvres should be performed if McRobert's and suprapubic pressure have been unsuccessful. The aim of these manoeuvres is to effect internal rotation of the shoulders or delivery of the posterior arm to reduce the bisacromial diameter.

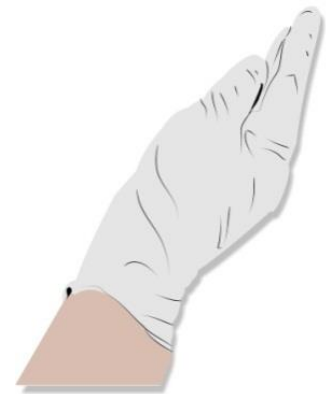NOTE: The following manoeuvres may be undertaken in any order according to need. There is no evidence that one manoeuvre is more successful than another but all begin with inserting the whole hand into the sacral hollow ⁴.

Normal downwards traction should be attempted after each manoeuvre to try to effect delivery.

Correct hand position

Correct hand position for insertion into the vagina is essential if internal manoeuvres are to be successful. The sacral hollow is the most spacious part of the pelvis; vaginal access can be gained more easily posteriorly. The correct hand position has been described 'as if putting on a tight bracelet' where the fingers are compressed and the thumb tucked in to the palm ⁴.

Correct hand position

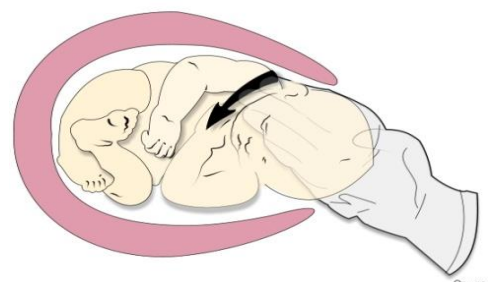


Rubin's II Manoeuvre

The accoucheur's hand is inserted into the vagina and digital pressure is applied to the posterior aspect of the anterior shoulder pushing it towards the fetal chest. This rotates the shoulders forward into the more favourable oblique diameter.

Completion of the birth is then attempted using normal downwards traction.

Rubin's II



Combined Rubin's II & Wood screw

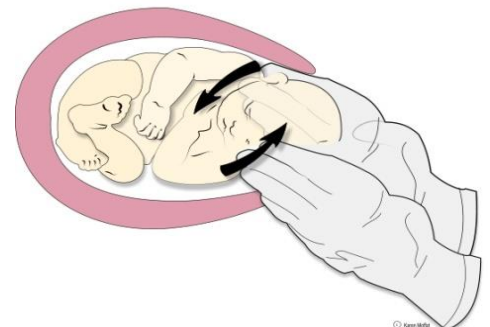
Wood's screw Manoeuvre

While maintaining the McRobert's position, the accoucheur introduces their second hand and locates the anterior aspect of the posterior shoulder.

Pressure is applied to rotate the posterior shoulder.

Completion of the birth should be attempted once the shoulders move into the oblique diameter.

If this movement is unsuccessful continue rotation through 180° and attempt delivery.



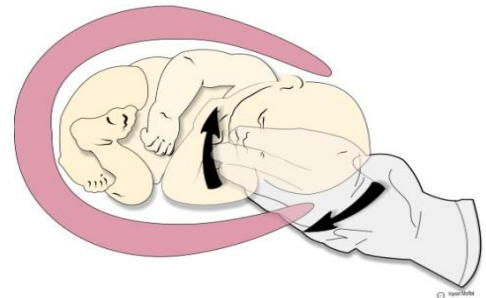
Shoulder Dystocia



Reverse Wood's screw Manoeuvre

Pressure is applied to the posterior aspect of the posterior shoulder attempting to rotate it through 180° in the opposite direction to that described in the Wood's screw manoeuvre.

Reverse Wood screw



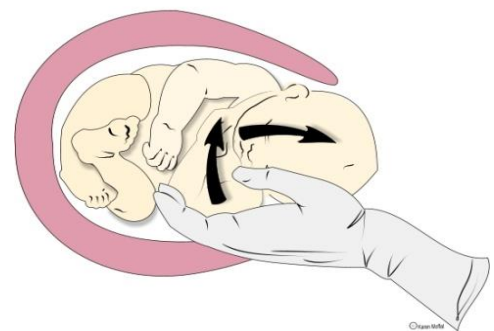
Delivery of the Posterior Arm

The fetus is usually in an attitude of flexion with the arms flexed over the chest.

The accoucheur passes their hand into the vagina over the chest of the fetus to identify the posterior arm and elbow. Apply pressure to the antecubital fossa to flex the elbow in front of the body, and / or grasp the posterior hand to sweep the arm across the chest and deliver the arm.

This is followed by rotation of the fetus into the oblique diameter of the pelvis, or through 180°, bringing the anterior shoulder under the symphysis pubis.

Remove the posterior arm

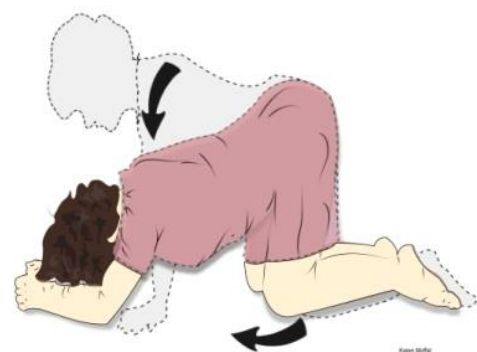

Rotation of the woman onto all fours

Rotation of the woman onto all fours may also facilitate delivery by increasing the pelvic diameters and allowing better access to the posterior shoulder.

While nomenclature of these manoeuvres may change within various textbooks, the management principles remain the same.

Roll over onto all-fours (maintain McRoberts's position)



Posterior axilla sling traction (PAST) technique ^{13,14}

The PAST technique makes use of a sling that is placed around the posterior axilla. The sling is typically a suction catheter or an in-out urinary catheter which is folded into a loop and threaded through the baby's posterior axilla. Downward traction can then be applied to the sling to deliver the posterior shoulder. If the posterior arm does not follow, it can be swept out more easily as room has been created by removing the posterior shoulder. The sling can also be used to rotate the shoulders if traction on the shoulder fails.

In order to rotate the shoulders, traction should be applied laterally towards the baby's back then anteriorly while digital pressure is applied behind the anterior shoulder to assist rotation.



The sling can be doubled or used singly. The doubled method provides more stability but the single method may be easier to insert and the extra length provides more grip.

The ends of the sling can be clamped to allow greater traction.

Please see this video '[Shoulder Dystocia](#)' for instructions on how to insert and apply the sling traction.

Precautions ⁴

Avoid strong downward traction until the shoulder is disimpacted. Excessive traction is associated with neonatal trauma including permanent brachial plexus injury.

Avoid jerking or tugging on the fetal head during traction as this may be more damaging to the brachial plexus.

Avoid fundal pressure. This is associated with increased incidence of brachial plexus injury.

4.4 Cord Management⁷

Shoulder dystocia, either without or with the presence of a nuchal cord places the infant at particular risk of hypovolaemia.

Compression on the cord or body of a tight fitting fetus may cause more fetal blood than usual to be extruded into the placenta. This situation may contribute to the poor condition of a number of infants at birth.

Cutting a tight nuchal cord prior to the birth of the shoulders has the potential to increase the infant's risk of asphyxia, cerebral palsy and even death if there is severe should dystocia. It is advisable to maintain an intact cord as far as possible.

Once the shoulders are free there are several options for management.

- Slip the cord over the head or down around the shoulders and slide the baby through the cord.
- Initiate the '[Somersault Manoeuvre](#)'. Deliver the baby slowly and bring the head as it is born towards the mother's thigh. Keep the baby low near the perineum while the body is delivered so that little traction is exerted on the cord.
- Avoid cutting the nuchal cord immediately after birth as the dynamics of cord compression will likely have resulted in an increased transfer of blood to the placenta. Pale colour and poor fetal tone equate with hypovolaemia of the infant. A delay in cord clamping is required for blood volume to equalise after birth and assist with the transition to neonatal life.
- If the cord needs to be divided immediately after birth the restoration of the infant's blood volume can be assisted by rapidly milking the cord two to four times from the introitus to the infant's umbilicus *before* cutting the cord³.

4.5 Documentation

Accurate documentation of actions taken to address this obstetric emergency is essential. Level II evidence supports the use of a standardised checklist for shoulder dystocia as this significantly improves the documentation of critical elements of the birth.

Documentation includes:

- The time of birth of the head
- Manoeuvres performed, the timing and sequence
- The direction the baby is facing and which shoulder is impacted (right or left)
- The time of delivery of the body
- Staff in attendance
- The condition of the baby at birth



Utilisation of the MCIS Shoulder Dystocia Form ensures all important information is recorded.

Consider also describing the shoulder dystocia by degree of difficulty in effecting the birth. The following examples have been suggested in the literature⁸.

GRADE	TREATMENT
Mild	McRoberts manoeuvre, Suprapubic pressure
Moderate	Rubin 2, Woods or reverse Woods manoeuvre, posterior shoulder delivery
Severe	Fracture clavicle or humerus
Undeliverable	Cephalic replacement and abdominal rescue

4.6 Debriefing

- Shoulder dystocia may be a traumatic situation for the mother and her birth partners.
- Clear communication and instructions to the woman and her birth partners is vital during the emergency.
- The emergency and the reason for the manoeuvres should be discussed after the birth.
- The baby should be assessed by a paediatrician to exclude or manage any fetal morbidity sustained.

Complications of Shoulder Dystocia

Maternal	Neonatal
3 and 4 th degree tears	Brachial plexus injury
PPH	Fractured humerus/clavicle
Uterine rupture	Hypoxia
Future obstetric issues	Death
Psychological effects of birth trauma	

4.7 Morbidities

Humeral and clavicular fractures²: can occur unintentionally or in the case of clavicular fracture as an intentional procedure to reduce the bisacromial diameter. These usually heal quickly and prognosis is good.

Brachial plexus injury²: The brachial plexus is a network of nerves that conducts signals from the spinal cord to the arm and hand. These nerves originate in the fifth, sixth, seventh and eighth cervical (C5-C8), and first thoracic (T1) spinal nerves, and innervate the muscles and skin of the chest, shoulder, arm and hand. Brachial plexus injuries, or lesions, are caused by damage to those nerves. Several categories of palsy are described as a result of injury to specific nerves.

- Erb's palsy is the most common brachial plexus injury and is characterised by a flaccid upper arm, an extended lower arm rotated towards the body and a hand in the 'waiter's tip' position. Erb's palsy generally recovers within 12 months.
- Klumpke's Palsy is less common and is characterized by a limp hand and no movement of the fingers. Recovery rate is lower than Erb's palsy with around 40% recovery within 12 months.



- A total brachial plexus injury is characterized by total sensory and motor deficit of the entire arm. Sympathetic nerve injury (Horner syndrome) can result in contraction of the pupil and ptosis of the eyelid on the affected side. Full recovery is rare without surgical intervention. Prognosis can be poor.

4.8 Incidence

Shoulder dystocia occurs in around 1% of all vaginal births⁹.

4.9 Risks

Assessment of risk factors for shoulder dystocia has a poor predictive value and elective caesarean birth is indicated only in diabetic women with macrosomia or where the estimated fetal weight is greater than 5 kg in non-diabetic women³. However there are antenatal and intrapartum risk factors of which clinicians should take note.

4.10 Prelabour

Previous shoulder dystocia: recurrence rate has been reported as at least 10%, however this rate may be an underestimate due to the number of women in this group who have subsequent elective caesarean births⁶.

Macrosomia: is a weak predictor as up to 50% of shoulder dystocias occur in babies within the normal weight range. There is a 10% occurrence in babies 4.0-4.999kg and 23% for babies greater than 4.5kg^{1, 6}. Third trimester ultrasound is a poor predictor of actual birth weight¹⁰.

Maternal diabetes mellitus: the risk factor for shoulder dystocia is increased by 3 to 4 times that for a baby of similar weight. It has been suggested that this could be due to the different body shape of babies with diabetic mothers¹.

Maternal obesity: it has been suggested that the link between shoulder dystocia and maternal obesity may be more likely due to fetal macrosomia than the obesity itself^{11, 12}.

5. Evaluation, monitoring and reporting of compliance to this guideline

To be developed.

6. References (evidence, best practice, websites, etc.)

1. Acker DB, Sacks BP, Freidman EA (1985) Risk factors for shoulder dystocia *Obstet Gynecol* 66:762-8
2. Benjamin K (2005) Distinguishing physical characteristics and management of brachial plexus injuries *Adv Neonatal Care* 5:240-51
3. Draycott T, Montague I, Fox R (2005) *Shoulder Dystocia* London RCOG Press
4. Draycott T, Winter C, Crofts J, Barnfield S (2008) PROMPT (Practical Obstetric Multiprofessional Training) Course Manual *RCOG Press London*
5. Gherman RB, Ouzian JG (1998) Obstetric manoeuvres for shoulder dystocia and associated fetal morbidity *Am J Obstet Gynecol* 178:1126-30
6. Ginsberg NA, Moisidis C (2001) How to predict recurrent shoulder dystocia *Am J Obstet Gynecol* 184:1427-30
7. Mercer JS, Erickson-Owens DA (2009) *The Midwifery View of Shoulder Dystocia* IN O'Leary JA *Shoulder Dystocia and Birth Injury*, Humana Press, a part of Springer Science and Business Media
8. O'Leary JA (2009) Delivery Techniques IN O'Leary JA *Shoulder Dystocia and Birth Injury*, Humana Press, a part of Springer Science and Business Media
9. Ouzonian JG, Gherman RB (2005) Shoulder dystocia: are historic risk factors reliable predictors? *Am J Obstet Gynecol* 192:1933-5



10. Rouse DJ, Owen J (1999) Prophylactic caesarean delivery for fetal macrosomia diagnosed by means of ultrasonography: a Faustian bargain? *Am J Obstet Gynecol* 181:332-8
11. Sandmire HF, O'Hallain TJ (1988) Shoulder dystocia: the incidence and associated risk factors *Int J Gynaecol Obstet* 26:65-73
12. Usha Kiran TS, Hemmadi S, Bethel J, Evans J (2005) Outcome of pregnancy in a woman with increased body index *BJOG* 112:768-72
13. Cluver CA, Hofmeyer GJ (2009) Posterior axilla sling traction: a technique for intractable shoulder dystocia *Obstet Gynaecol* 113:486-8
14. Cluver CA, Hofmeyer GJ (2015) Posterior axilla sling traction for shoulder dystocia: case review and a new method of shoulder rotation with a sling. *American Journal of Obstetrics and Gynaecology* June 784 e1-e7

7. Legislation/Regulations related to this guideline

Not applicable.

8. Appendices

Appendix 1: [Shoulder Dystocia Algorithm](#)

Please ensure that you adhere to the below disclaimer:

PGP Disclaimer Statement

The Royal Women's Hospital Clinical Guidelines present statements of 'Best Practice' based on thorough evaluation of evidence and are intended for health professionals only. For practitioners outside the Women's this material is made available in good faith as a resource for use by health professionals to draw on in developing their own protocols, guided by published medical evidence. In doing so, practitioners should themselves be familiar with the literature and make their own interpretations of it.

Whilst appreciable care has been taken in the preparation of clinical guidelines which appear on this web page, the Royal Women's Hospital provides these as a service only and does not warrant the accuracy of these guidelines. Any representation implied or expressed concerning the efficacy, appropriateness or suitability of any treatment or product is expressly negated

In view of the possibility of human error and / or advances in medical knowledge, the Royal Women's Hospital cannot and does not warrant that the information contained in the guidelines is in every respect accurate or complete. Accordingly, the Royal Women's Hospital will not be held responsible or liable for any errors or omissions that may be found in any of the information at this site.

You are encouraged to consult other sources in order to confirm the information contained in any of the guidelines and, in the event that medical treatment is required, to take professional, expert advice from a legally qualified and appropriately experienced medical practitioner.

NOTE: Care should be taken when printing any clinical guideline from this site. Updates to these guidelines will take place as necessary. It is therefore advised that regular visits to this site will be needed to access the most current version of these guidelines.

Shoulder Dystocia Algorithm

